

Practical 1 Worksheet

ANATOMICAL TERMS

1. Use the word bank to fill in the missing words.

reference	side	stand	body	arms	palms	anatomical	forward
-----------	------	-------	------	------	-------	------------	---------

All anatomical terms have a(n) _____ point which is called the _____ position. This is a(n) _____ facing position where you _____ up, with your _____ by your _____, with the _____ of your hands facing forward.

2. Complete these sentences using the terms **superior** or **inferior**. Assume the individual is in anatomical position.
- The hands are _____ to the feet.
 - The knees are _____ to the waist.
 - The elbow is _____ to the wrist.
 - The calf muscle is _____ to the ankle.
3. Complete these sentences using the terms **anterior** or **posterior**. Assume the individual is in anatomical position.
- The heel is _____ to the toes.
 - The biceps are _____ to the triceps.
 - The hamstrings are _____ to the quadriceps.
4. Complete these sentences using the terms **lateral** or **medial**. Assume the individual is in anatomical position.
- The arms are _____ to the midline.
 - The neck is _____ to the arms.
 - The shoulders are _____ to the midline.
5. Complete these sentences using the terms **superficial** or **deep**. Assume the individual is in anatomical position.
- The skin is _____ to the muscles.
 - The heart is _____ to the ribs.
6. Choose the correct answer. Assume the individual is in anatomical position.
- The big toe is on the **lateral/medial** side of the foot.
 - The shoulder blade is on the **anterior/posterior** side of the body.
 - The hand is **distal/proximal** to the elbow.
 - The hips are **superior/inferior** to the shoulders.
 - The shoulders are **medial/lateral** to the spine.
 - The knee is **distal/proximal** to the ankle.
 - The knee is **superior/inferior** to the ankle.
7. What is the importance of having the anatomical position?
8. Johnny's doctor taps him on the knee and his leg kicks out (straightens). What motion did his knee make?

9. Jewel has just pointed her toe in dance class. What motion did she make?
10. Joe has just stretched both arms upwards to try and wake himself up in class. What motion did he make at his shoulders?
11. Jessica has just turned her foot to point out to the side in ballet class. What motion did she make with her hip?
12. Jamal is doing jumping jacks. What motion occurs at his hips as his feet move toward the middle?
13. Jennifer swings her leg, straightened, out to the side to close a door with her foot. What motion did she make with her leg?

BONES

14. Is the auricular surface of the os coxae found on the medial or lateral side of the bone?
15. Is the acetabulum found on the medial or lateral side of the bone?
16. Is the ischial tuberosity found on the anterior or posterior side of the bone?

Determine if the os coxae in your box is from the left or right side.

17. What does the word “foramen” mean?
18. Which portion of the femur fits in the acetabulum?
19. How does the pubic arch of a male compare to the pubic arch on a female pelvis?
20. In general, what is the purpose of the bony bumps (e.g., greater trochanter, ischial tuberosity, tibial tuberosity)?
21. For the greater and lesser trochanters:
 - a. Which is more proximal?
 - b. Which is larger?
 - c. Which is more medial?
22. On the femur, what is the easiest way to tell which condyle is the medial condyle and which is the lateral condyle?
23. What does the word “epicondyle” mean?
24. On the femur, the epicondyles are superior/inferior to the condyles.
25. On the femur, the epicondyles are proximal/distal to the condyles.
26. What does the word fossa mean?
27. The shaft of the femur is proximal/distal to the trochanters.

Determine if the femur in your box is from the left or right side.

28. What features helped you determine if the femur was from the right or left side of the body?
29. Will the patella be found on the anterior or posterior side of the knee?

30. How can you tell the difference between the tibia and fibula?
31. Is the head of the fibula on its proximal or distal end?
32. What features help you decide if you are looking at the lateral malleolus or the head of the fibula?
33. On the tibia, what is the best way to identify the medial condyle?
34. Is the tibial tuberosity on the anterior or posterior portion of the tibia?
35. If you touch your feet together, which of these will be touching: lateral malleoli or medial malleoli?
36. Do all the toes have the same number of phalanges?
37. Is the big toe on the medial or lateral side of the foot?
38. Which is more proximal: metatarsals or tarsals?
39. What is the difference between the tarsals and the talus?

KNEE

40. What is the easiest way to tell medial from lateral on the knee joint (model or cadaver)?
41. What two bony structures does the lateral collateral ligament attach?
42. Which of the collateral ligaments is larger (ie. is thicker/wider): medial or lateral?
43. Can you see the anterior cruciate ligament from both the anterior and posterior side of the knee?
44. Can you see the posterior cruciate ligament from both the anterior and posterior side of the knee?
45. On the posterior side, does the anterior cruciate ligament attach more on the medial or lateral side of the intercondylar fossa?
46. The medial meniscus helps to pad which two bony regions?
47. Is the quadriceps femoris tendon more proximal or distal than the patellar ligament?
48. Is the quadriceps femoris tendon more superior or inferior than the patellar ligament?
49. The patellar ligament attaches to the patella and which bony landmark on the tibia?
50. From their anatomy, which of the cruciate ligaments is more likely to prevent the tibia from sliding anteriorly (or the femur sliding posteriorly)?

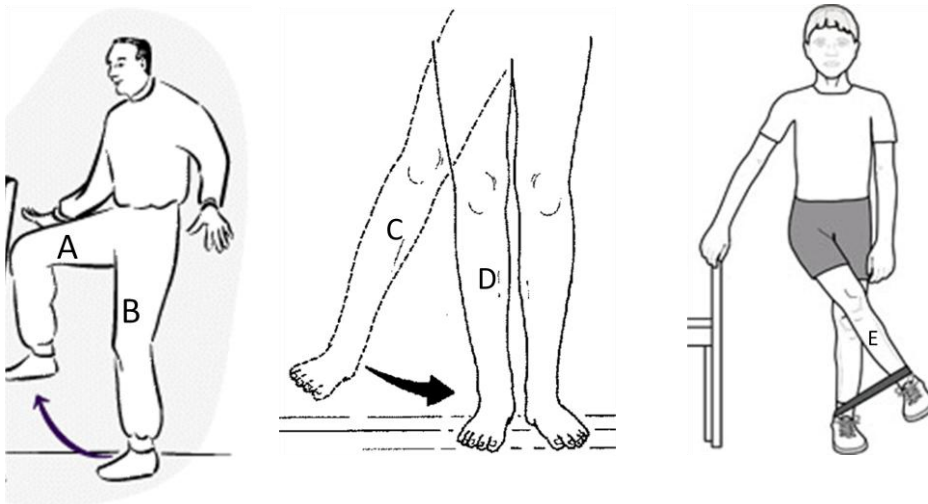
ABDOMEN

51. Where is the xiphoid process?
52. Based on their anatomy, will the abdominal muscles cause hip flexion? Why or why not?
53. List these muscles from superficial to deep: transversus abdominis, external abdominal oblique, internal abdominal oblique.
54. What does "oblique" mean? What does "rectus" mean?
55. Starting from the midline, which abdominal muscle fibers run:
 - a. superior-laterally
 - b. infero-laterally
 - c. vertically
 - d. horizontally

HIP/THIGH

56. What function do all of the deep muscles of the hip have in common (i.e., piriformis, gemellus superior, obturator internus, gemellus inferior, quadratus femoris)?
57. What can be a way to tell the difference between piriformis and gemellus superior?
58. What is the common origin for all three gluteal muscles?
59. Which of the gluteal muscles does not insert on the greater trochanter?
60. How does the size/shape/location of the greater trochanter help with rotation?
61. Do you think the muscles doing lateral rotation of the hip are more likely to originate from the anterior or posterior side of the ischium? Why?
62. Where does “quadratus femoris” get its name?

Use these drawings for the next questions (#63-66):



63. Which thigh is showing hip extension (A, B, C, D, or E)?
Give four muscles that contribute to hip extension :
64. Which leg is showing an ABducted hip (A, B, C, D, or E)?
Give two muscles that contribute to abduction of the thigh:
65. What hip action is being shown in figure A?
What muscle is primarily causing this action?
66. What hip action is being shown in figure E?
Give four muscles that contribute to this hip action:

67. Where does 'iliotibial band' get its name?
Is it on the medial or lateral side of the thigh?
68. Which is more superficial: adductor longus or adductor brevis?
69. Are the hamstring muscles found on the more posterior or anterior side of the thigh?
70. Which two hamstring muscles are found on the lateral side?
71. Which two hamstring muscles are found on the medial side?
72. Which is more superficial: semitendinosus or semimembranosus?
73. Three of the four hamstring muscles originate from which bony landmark?
74. Which single hamstring muscle does not share this origin?
What is different about the action of this muscle from the other three?

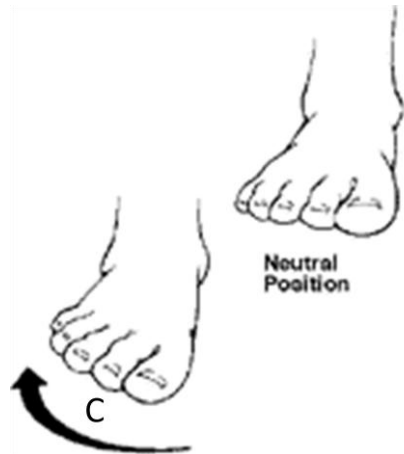
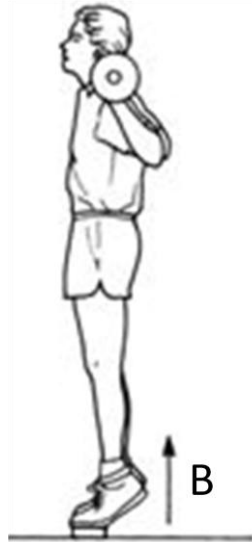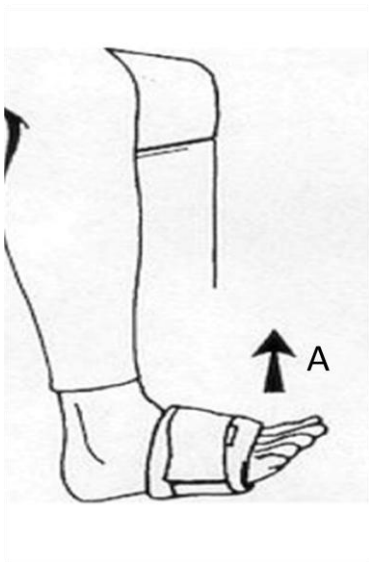
Why?

What action do all four hamstring muscles share?
75. All of the heads of the quadriceps femoris muscle have what common function?
What common insertion do they share?

LEG/FOOT

76. Both the flexor hallucis longus and extensor hallucis longus insert on which bone?
77. What does that tell you about the word "hallucis"?
78. Why do both the soleus and gastrocnemius cause plantar flexion?
79. Why does only the gastrocnemius cause knee flexion but soleus does not?
80. Just based on the name, would you expect fibularis longus to be on the medial or lateral side of the leg?
81. What is unusual about the arrangement of flexor hallucis longus and flexor digitorum longus (muscle location vs. insertion location)?
82. Would the tendons that pass under the extensor retinaculum be from muscles on the anterior or posterior side of the leg?
83. Flexor hallucis brevis is not on our list, but where do you think it would be located?
84. Is tibialis posterior superficial or deep to soleus?
85. Is soleus superficial or deep to gastrocnemius?
86. Do the tendons for flexion of the toes pass through the plantar or dorsal side of the foot?

Use these drawings for the next questions (#87-90):



87. What is the action shown:

- a. in A:
- b. in B:
- c. in C:

88. What is a common insertion for the two muscles that cause action B?

89. Are the muscles that cause action C on the anterior, posterior, medial, or lateral side of the leg?

90. Besides tibialis anterior, what two muscles on your list might be able to help with action A?